



Evidence Based Medicine --

Low Back Pain

THOMAS A. COURY, DO

PHYSICAL MEDICINE & REHABILITATION

DESERT SKY SPINE & SPORTS MEDICINE

4/27/2017

EBM-- LBP

- ▶ First, a dive into the literature on the topic of low back pain, its diagnosis, and treatment options
- ▶ Then, a pull-back big picture scope to generate take-home, primary care pearls

My background

- ▶ Doctor of Osteopathic Medicine at Kirksville College of Osteopathic Medicine (2005)
- ▶ Physical Medicine & Rehabilitation Residency at the University of Kentucky (2009)
- ▶ Spine & Sports Medicine at Southwest Spine & Sports in Scottsdale, AZ (2010)
- ▶ Established Desert Sky Spine & Sports in Oro Valley in the summer of 2010

Desert Sky Spine & Sports Medicine

Focus on function – Returning or maintaining patients' ability to perform their vocational and avocational activities

Musculoskeletal Medicine / Pain (80%) – Spine Medicine, Workers Compensation Injuries, Sports Injuries, Electrodiagnostic Medicine, Spinal Cord Stimulator & Intrathecal Pump Management

General PM&R (20%) – Traumatic Brain Injury, Spinal Cord Injury, wheelchair/mobility management, Inpatient Rehabilitation coverage, Spasticity Management

One board certified PM&R Physician, 3 NPs, 2 PAs

Locations – Oro Valley, East Tucson, Sierra Vista, Safford

Low Back Pain – Etiology?

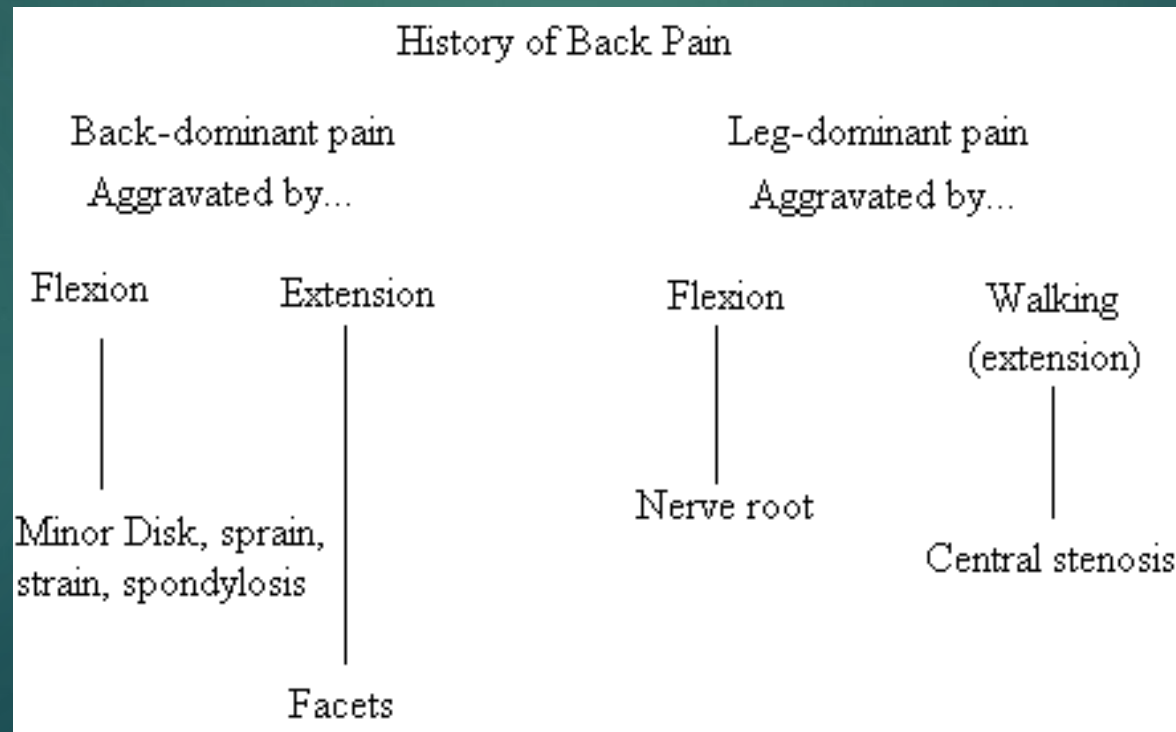
- ▶ Spinal column – facet joint, disc, neural encroachment, spinal stenosis, spondylolisthesis, vertebral body fracture
- ▶ Muscular – spasm, muscular imbalances
- ▶ Systemic – Metastases, infectious (diskitis), TB
- ▶ Somatic Dysfunction – altered pelvic alignment, L5/S1 abnormalities
- ▶ Psychologic/Central – stress, opioid-induced hyperalgesia
- ▶ Malingering – compensation issues

Is “Low back pain” a dx?

- ▶ There is an ICD-10 code for low back pain
- ▶ LBP and CLBP are symptoms, not dx by themselves
- ▶ The dx may be singular or multi-factorial, but it is an intellectual short-cut to simply call it Low Back Pain
- ▶ Diagnosis and treatment of low back pain is both harder than you think and easier than you think
- ▶ Need to deconstruct the mindset of “physical therapy, pain meds, injections, surgery”

How can we dx LBP?

- ▶ History – In the absence of psychological or malingering sources, most patients will declare the source of their back pain, simply by giving a good history.



Physical examination

- ▶ I utilize my physical examination to confirm/deny my differential diagnosis created when taking the history.
- ▶ I pay particular attention to the physical examination when the historical picture is unclear, or if multiple etiologies for their pain stand out.
- ▶ A strong foundation in musculoskeletal and peripheral nervous system anatomy helps greatly in teasing out a confusing history (ex – negative SLR)

Imaging <https://acsearch.acr.org/docs/69483/Narrative/>

- ▶ Acute low back pain, no red flags, no prior treatment – no imaging required
- ▶ Acute, subacute, or chronic uncomplicated low back pain or radiculopathy. One or more of the following: low velocity trauma, osteoporosis, elderly individual, or chronic steroid use. – X-ray, CT Scan without contrast, ?MRI?
- ▶ Acute, subacute, or chronic low back pain or radiculopathy. One or more of the following: suspicion of cancer, infection, or immunosuppression. – MRI with contrast > CT Scan with contrast > X-ray > SPECT scan
- ▶ Acute, subacute, or chronic low back pain or radiculopathy. Surgery or intervention candidate with persistent or progressive symptoms during or following 6 weeks of conservative management. -- MRI without contrast > CT scan with contrast > CT myelogram > X-ray

Imaging

<https://acsearch.acr.org/docs/69483/Narrative/>

- ▶ Low back pain or radiculopathy. New or progressing symptoms or clinical findings with history of prior lumbar surgery. – MRI with contrast > CT with contrast > CT without contrast > CT myelogram
- ▶ Low back pain with suspected cauda equina syndrome or rapidly progressive neurologic deficit. – MRI without contrast > CT Myelogram > CT with contrast

Imaging – Take-aways

- ▶ Acute, non-complicated low back pain does not require any imaging
- ▶ MRI without contrast is the preferred modality for imaging soft-tissue structures, such as disc and nerve
- ▶ CT is preferred when suspicion of bone lesion
- ▶ Contrast is reserved for systemic/metabolic concerns or post-surgical evaluation
- ▶ CT Myelogram is usually not necessary
- ▶ SPECT scan is rarely helpful

Imaging – Plain Films

- ▶ I order flexion-extension films on anyone with a spondylolisthesis, just to check for spinal instability (>4 mm difference)
- ▶ Plain films are useful in cases of minor trauma, or in patients with previous hx of osteoporotic fractures, where a CT is not necessary to demonstrate a “new” fx
- ▶ In cases of suspected metastatic cancer, I will order an MRI with contrast, then leave the decision of further studies to the oncologist.

Imaging

[Phys Med Rehabil Clin N Am.](#) 2010 Nov;21 (4):725-66. doi:
10.1016/j.pmr.2010.07.004. (Maus, T.)

Imaging is an integral part of the clinical examination of the patient with back pain; it is, however, often used excessively and without consideration of the underlying literature. The primary role of imaging is the identification of systemic disease as a cause of the back or limb pain; magnetic resonance imaging (MRI) excels at this. Systemic disease as a cause of back or limb pain is, however, rare. Most back and radiating limb pain is of benign nature, owing to degenerative phenomena. There is no role for imaging in the initial evaluation of the patient with back pain in the absence of signs or symptoms of systemic disease. When conservative care fails, imaging may be undertaken with due consideration of its risks: labeling the patient as suffering from a degenerative disease, cost, radiation exposure, and provoking unwarranted minimally invasive or surgical intervention. Imaging can well depict disc degeneration and disc herniation. Imaging can suggest the presence of discogenic pain, but the lack of a pathoanatomic gold standard obviates any definitive conclusions. The imaging natural history of disc herniation is resolution. There is very poor correlation between imaging findings of disc herniation and the clinical presentation or course. Psychosocial factors predict functional disability due to disc herniation better than imaging. Imaging with MRI, computed tomography (CT), or CT myelography can readily identify central canal, lateral recess, or foraminal compromise. Only when an imaging finding is concordant with the patient's pain pattern or neurologic deficit can causation be considered. The zygapophysial (facet) and sacroiliac joint are thought to be responsible for axial back pain, although with less frequency than the disc. Imaging findings of the structural changes of osteoarthritis do not correlate with pain production. Physiologic imaging, either with single-photon emission CT bone scan, heavily T2-weighted MRI sequences (short-tau inversion recovery), or gadolinium enhancement, can detect inflammation and are more predictive of an axial pain generator.

Imaging -- MRI

- ▶ There is very poor correlation with an MRI finding and a patients symptoms of pain
- ▶ Disc degeneration is not a disease, it is part of the natural aging process
- ▶ Osteoarthritis and degenerative discs can be ubiquitous in patients without any low back symptoms
- ▶ Similarly, patients can have debilitating low back pain in the absence of MRI findings

Imaging – take-aways

- ▶ Make sure you correlate the history and physical examination with imaging to make a diagnosis. Patients do not necessarily need injections to prove the etiology of their back pain, but do not assume an MRI finding to be the source of their pain.
- ▶ Is it possible for someone to have a very large herniated disc on MRI, but the etiology of their pain is facet arthropathy? Absolutely, yes.
- ▶ Do NOT treat pictures. Treat patients.

Low back pain –

Radiculopathy

- ▶ Flexion-based pain, with leg symptoms > back symptoms
- ▶ Most likely scenario is neural impingement from a lumbar herniated disc
- ▶ Other possibilities include anything that can narrow the neuroforamen (facet synovial cyst or facet hypertrophy, or any space occupying lesion)

- ▶ Begin with time, relative rest, anti-inflammatory medications
- ▶ If neurological weakness is present, keep a close follow-up to track progression. If no improvement, or weakness worsening, order an MRI without contrast
- ▶ Epidural steroid injections provide good, short-term benefit (FDA)
- ▶ Remember that the natural history of a herniated disc on MRI is resolution
- ▶ Treat the nerve, not the disc
- ▶ If no improvement with ESI, refer for surgical evaluation

Low back pain –

Facet etiology

- ▶ Extension-based pain, with low back (or lateral hip) pain > leg pain
- ▶ Diagnostic gold standard for facet mediated low back pain is a local anesthetic block of the lumbar medial branch nerve, followed by a control block of the same. (Lumbar medial branch block)
- ▶ Start with anti-inflammatory medication, relative rest, physical therapy
- ▶ Manipulation can be quite beneficial for facet pain
- ▶ If no improvement, consider lumbar medial branch blocks, followed by lumbar radiofrequency ablation. Consider return to PT following RFA.

“...the majority of the studies focusing on lumbar facet joints and sacroiliac joints suggest that RFA significantly reduces pain in short-term follow-up” (Leggett, L. et al, **Radiofrequency ablation for chronic low back pain: A systematic review of randomized controlled trials**)

Low back pain –

Spinal stenosis

- ▶ Extension (i.e., walking) based pain, with neurogenic claudication
- ▶ Begin with an assessment of muscular weakness. Consider analgesic medication, including neuropathic agents. Consider physical therapy.
- ▶ If significant limitation in function is noted (I can only walk 50 feet, etc), order an MRI without contrast
- ▶ Consider Epidural Steroid Injections
 - ▶ Short-term, modest benefit (FDA)
 - ▶ The beneficial effect may not be the steroid at all (LESS trial)
 - ▶ Could be considered as a bridge to physical therapy
- ▶ Consider trial of a Spinal Cord Stimulator
- ▶ If conservative measures are not successful, refer for Surgical Evaluation

Low back pain –

Discogenic etiology

- ▶ Axial low back pain, worse with flexion, improved with extension. Stabbing in nature. Worse with sitting or standing in one position for prolonged periods. No radiating pain. No psychosocial factors or barriers. Muscular imbalances / weak musculature not a factor. All other spinal etiologies ruled-out.
- ▶ Can the disc be a source of pain? There is afferent innervation of the posterior annulus.
- ▶ Discogenic back pain is probably overdiagnosed by those who agree with its existence, and underdiagnosed by those who deny its existence.

Discogenic back pain – how often dx?

- ▶ I diagnose discogenic low back pain in less than 10 or so patients per year. They are relatively young, highly motivated, often working, without evidence of underlying anxiety / depression, with fairly strong core musculature.
- ▶ In this population, tightly controlled, guideline-based, provocation discography is diagnostic. I do this procedure on less than one patient per year, on average.
- ▶ Take-away – While discogenic low back pain is a real etiology, low back pain is much, much more likely to be caused from something else (weak core, facet, muscular imbalance, psychosocial factors, etc.)

Why physical therapy?

- ▶ The amount of weight it takes to collapse a cadaveric spine, in the absence of musculature, is about 35 pounds. (___)
- ▶ Tonic contract of the core muscles allows the body to be held up.
- ▶ Low back pain creates a “downward spiral” of perceived immobility, causing weakening of core muscles, causing increased pain, causing more perceived immobility.
- ▶ The primary role of PT is to reverse this spiral.

Physical Therapy— quality?

- ▶ Make sure to know who you are referring to
- ▶ I have a professional relationship with the physical therapy locations I refer to
- ▶ I use patient feedback to continually assess the quality of the therapy
- ▶ Be careful. Physical therapy is under the same pressures as physicians to see as many patients in a day as possible. Make sure your patients are not just put on an exercise bike for 30 minutes without supervision.
- ▶ My rule-of-thumb. If the physical therapist has a better working knowledge of the neuromusculoskeletal system than I do, chances are they are pretty good.
 - ▶ How do I know? I talk to them.

Physical therapy –

who needs it?

- ▶ Can a highly motivated individual use Google and YouTube and come up with their own home exercise core program?
 - ▶ Answer: Probably. But maybe their muscular imbalances are not going to improve with just core strengthening
- ▶ Can a personal trainer do the same job as a physical therapist?
 - ▶ Answer: Probably not. But if the personal trainer is a good motivator for the patient to exercise, go for it.
- ▶ Do NFL players, personal trainers, physicians, and even physical therapists, need to go see a physical therapist sometimes?
 - ▶ Answer: Absolutely, yes. Just because someone is a gym rat, doesn't mean they cannot benefit from physical therapy.

Lumbar bracing –

spinal orthoses, LSO, lumbar supports

- ▶ Review of literature does not support the use of lumbar bracing for patients with low back pain. (Cochrane)

Specific exercise programs / systems –

Tai Chi, Yoga, aquatic, etc

- ▶ Literature supports each of these.
- ▶ It is not difficult to design a study that demonstrates the effectiveness of a particular pet exercise program or system.
- ▶ As long as someone is moving in a physiologic range of motion, strengthening their core, and stretching tight muscles, they are probably doing it right.
- ▶ Don't forget aerobic conditions. Every man, woman, and child would benefit from 30 minutes of elevated heart rate daily, with very, very few exceptions. (ACSM, paraphrased)

Case study

- ▶ 38 y/o male PM&R physician with a 2 month history of low back pain. Intermittent in nature. Worse in the morning. Stiff, aching, occasional stabbing pain. Relieved with heat and stretching.
- ▶ Wears lead vest 2-3 days per week.
- ▶ Often travels 2-3 hours to get to rural clinics
- ▶ Under stress to manage a medical practice, raise a family, plan for retirement
- ▶ Active triathlete, competing in several races per year.
- ▶ Working diagnosis is weak core, tight hamstrings