

ACUTE AND CHRONIC NEUROPATHIES

27th Annual Southwestern Conference on Medicine
Westin La Paloma Resort and Spa
Tucson, Arizona

Scott Spradlin D.O. ,FACP,FACOI

I have no **relevant financial or nonfinancial relationships** in the products or services described, reviewed, evaluated or compared in this presentation.

Acute and Chronic Neuropathies

- *Neuropathy*- is defined as nerve disease/damage
- 20 million people suffer from some form of neuropathy
- Can be acute or chronic
- As you age the incidence is more
- Diabetic neuropathy is the most common neuropathy
- Most **common** neurological problem seen in a primary care office

Acute and Chronic Neuropathies

Presenting Signs and Symptoms-

- **Sensory**-earliest symptom
 - Numbness
 - Pain,
 - Anesthesia,
 - Ataxia, loss of coordination,
 - Temperature, vibratory sensation loss
- **Motor**-
 - Weakness,
 - Atrophy,
 - Fasciculation
 - Areflexia
- **Autonomic**-
 - Dry mouth, Dry eyes,
 - Bladder dysfunction,
 - Orthostatic hypotension,
 - Cold sensation , skin changes

Acute and Chronic Neuropathies

- **Mononeuropathy**
 - one nerve with one point of impingement
- **Mononeuropathy multiplex**
 - one nerve with multiple points impingement
- **Polyneuropathy**
 - multiple nerves and multiple points impingement

Case Presentation

72-year-old man presents to your outpatient clinic with the complaint of recurrent spells of hand numbness. On exam he has weakness of finger spreading. He also has sensory loss in the last two fingers splitting the ring finger. The most likely etiology for his symptoms is

- A. Recurrent transient ischemic attacks (TIAs)
- B. C6 radiculopathy
- C. C7 radiculopathy
- D. Ulnar neuropathy

Case Presentation

72-year-old man presents to your outpatient clinic with the complaint of recurrent spells of hand numbness. On exam he has weakness of finger spreading. He also has sensory loss in the last two fingers splitting the ring finger. The most likely etiology for his symptoms is

- A. Recurrent transient ischemic attacks (TIAs)
 - B. C6 radiculopathy
 - C. C7 radiculopathy
 - D. Ulnar neuropathy
- Answer:
- Ulnar Neuropathy(D)*

Acute and Chronic Neuropathies

- **Clinical Workup-**

- Personal/Family History/Exposures
- Alcohol use
- Glucose/HgA1c
- Sedimentation rate
- Creatinine- Comprehensive panel
- TSH-Thyroxine
- Complete Blood Count
- Vitamin Deficiencies (such as B-12)
- Pertinent Radiographic films
- EMG-NCV

Acute and Chronic Neuropathies

Focal Compressive Radiculopathies:

- Localized peripheral nerve
- Usually from compression
- Must differentiate from multiplex
- Examples:
 - Radial neuropathy- *radial nerve injury*
 - Carpal tunnel syndrome- *median nerve injury*
 - Ulnar neuropathy- *ulnar nerve injury*
 - Sciatic nerve- *sciatic nerve injury*
 - Peroneal nerve compression- *peroneal nerve injury*
 - Brachial neuritis- *brachial nerve injury*

Acute and Chronic Neuropathies

Mononeuropathy Multiplex

Diabetic Neuropathy- MOST COMMON

Alcoholic Neuropathy- *vitamin deficiency*

Bell's Palsy- *CN VII or Facial nerve*

Multiple Sclerosis (MS)- *demyelination*

Acute and Chronic Neuropathies

Polyneuropathies

- Landry-Guillain-Barre- *most common* autoimmune
- Diabetic Peripheral Neuropathy- *most common* overall
- Hereditary Motor and Sensory Neuropathy
- Chronic Inflammatory Demyelinating Polyneuropathy (CIDP) – Treatment is IVIG
 - Steroids make it better
- Other
 - HIV-
 - Toxicity- usually sensory-
 - (Thallium, Organophosphates, Lead)
 - Nutritional- Thiamine, B6, B12 Deficiencies
 - Paraneoplastic-
 - Rheumatologic-

Acute and Chronic Neuropathies

Hereditary Motor and Sensory Neuropathy

- Also known as “Charcot-Marie-Tooth”
- Most common inherited polyneuropathy
- Two main types: Type I and Type II
- Autosomal recessive or autosomal dominant
- Slow onset- gradual onset over years
- Foot drop/weakness
- Sensory loss in a stocking distribution

Acute and Chronic Neuropathies

• Landry-Guillain-Barre

- Most common inflammatory polyneuropathy
- Ascending paralysis/weakness limbs
- Areflexia
- Causes: Preceding infectious illness (2/3)
 - CMV EBV VARICELLA
 - Campylobacter Influenza Rabies
- CSF: elevated protein and slight increase cell count
- Treatment:
 - Plasmaphoresis
 - IVIG
 - Steroids of no use

Acute and Chronic Neuropathies

- Case 1

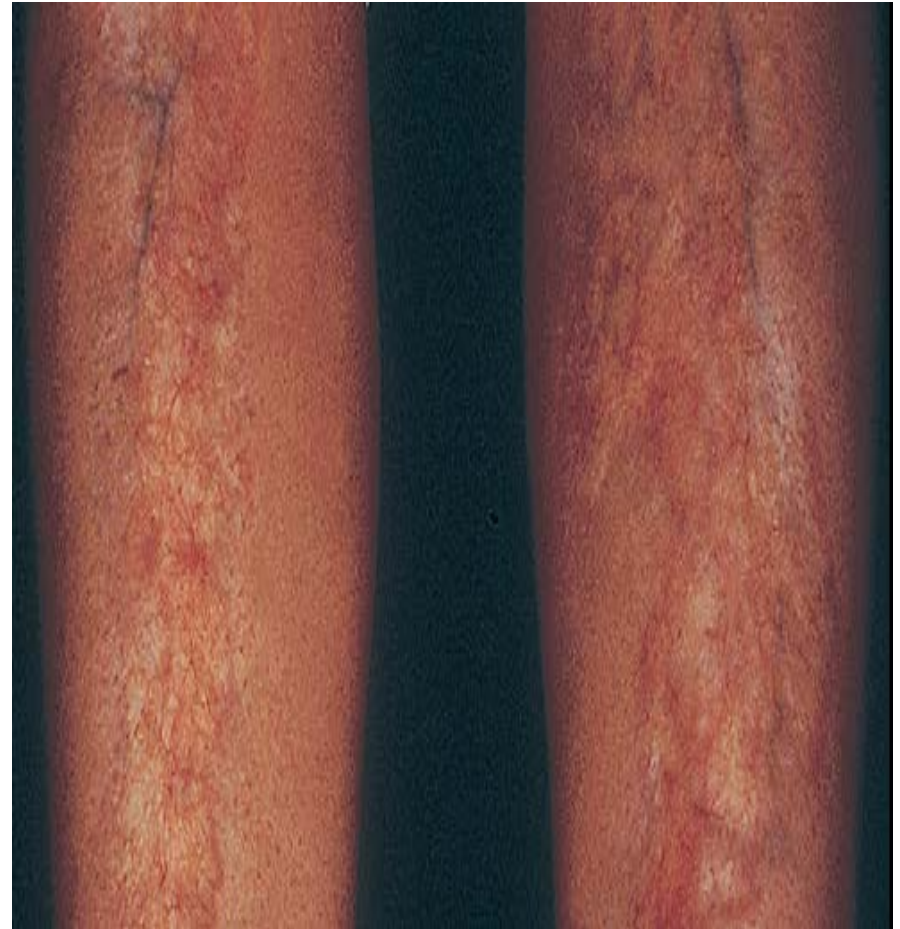
A 52-year-old man presents with 2 years of gradual progressive burning, stinging, and tingling in the feet present in the upper extremities but to a lesser extent.

Shoes, socks, and even the light touch of bed sheets are very irritating and limit his ability to rest.

When walking the pain becomes more severe (like an electrical shock sensation).

The examination shows-

- Decreased sensation in a stocking-glove pattern which is symmetric.
- Muscle strength is normal.
- The muscle stretch reflexes are absent at the ankles otherwise normal



Acute and Chronic Neuropathies

Diagnosis:

Chronic Progressive Sensory Neuropathy

Metabolic- Diabetes, HIV, Myeloma, or Porphyria

Alcohol-

Nutritional-

Vascular-

Toxic- occupational exposure

Rheumatologic/Musculoskeletal-

Acute and Chronic Neuropathies

• **Diagnostics-**

- Glucose, Hemoglobin A1C
- Sedimentation rate(ESR)
- TSH
- Complete Blood Count(CBC)
- Comprehensive Metabolic Panel
- SPEP,
- ANA, VitaminB12, and B1

Treatment of neuropathic pain

- **Trigeminal neuralgia (sharp stabbing face pain)**
 - **Carbamazepine/Oxcarbazepine**
Gabapentin
Lamotrigine
Baclofen
- **Limb neuralgia (sharp, stabbing, zinging, lightning, bee-sting pain)**
 - Gabapentin**
 - Pregabalin**
 - Duloxetine
 - Lamotrigine
 - Topomax
 - Lidocaine/Capsaicin
- **Continuous burning dysesthesias and supersensitivity (as in a diabetic)**
 - Pregabalin**
 - Gabapentin**
 - Venlafaxine**
 - Duloxetine
 - Tricyclic Antidepressants (such as Nortriptyline and Amitriptyline)
 - Tramadol

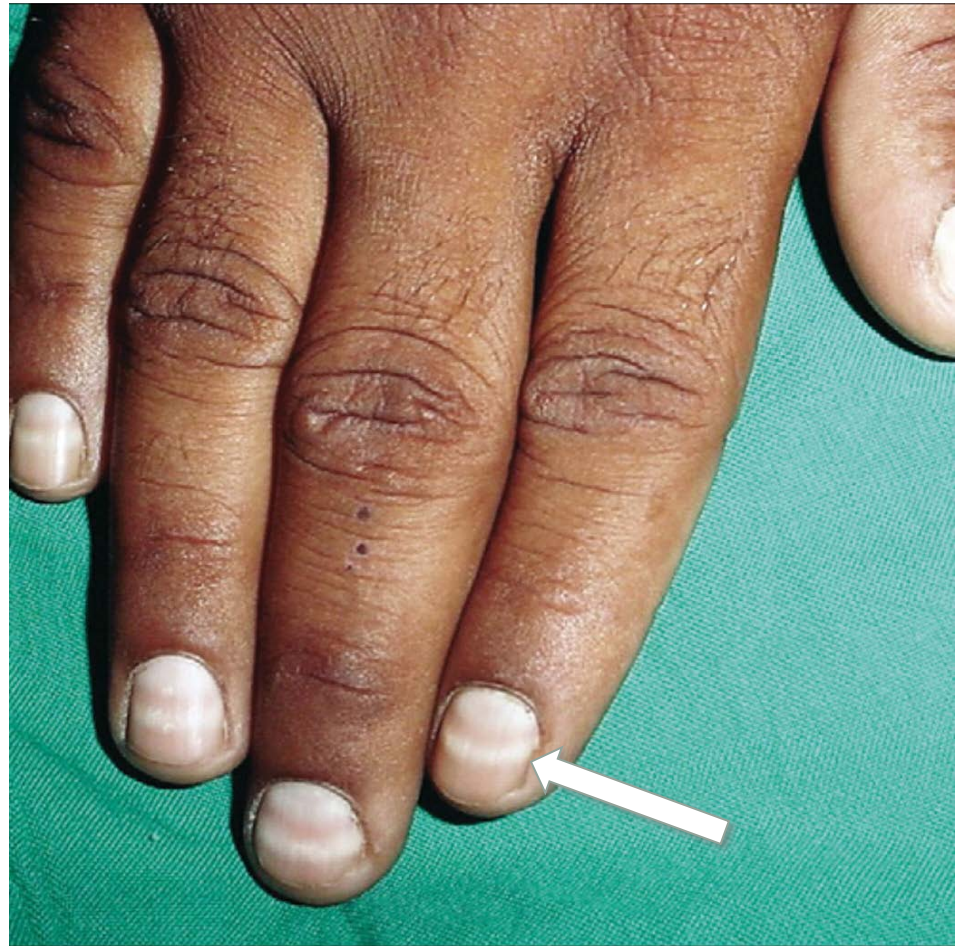Second Line-

Topical Lidocaine/Capsaicin
Tramadol

Acute and Chronic Neuropathies

- **Case 2**

- A 24-year-old man presents with 5 days of progressive burning, stinging, and tingling in the feet, gradually ascending up the legs
- Creeping into the hands symmetrically.
- On the day of presentation he has difficulty walking because of the development of bilateral foreleg weakness with foot drop.
- A few days before the onset of his sensory symptoms he had a severe 24-hour gastrointestinal syndrome
- The examination shows distal sensory loss in a stocking-glove pattern, muscle stretch reflexes are absent, and foot drop bilaterally
- Hands are shown in picture



Acute and Chronic Neuropathies

- Answer:
- Heavy Metal Poisoning-
 - probably Arsenic or Thallium

Acute and Chronic Neuropathies

- Case 3

29-year-old man presents after waking up with intense aching pain in the right jaw and ear.

He has sagging of the right side of the face.

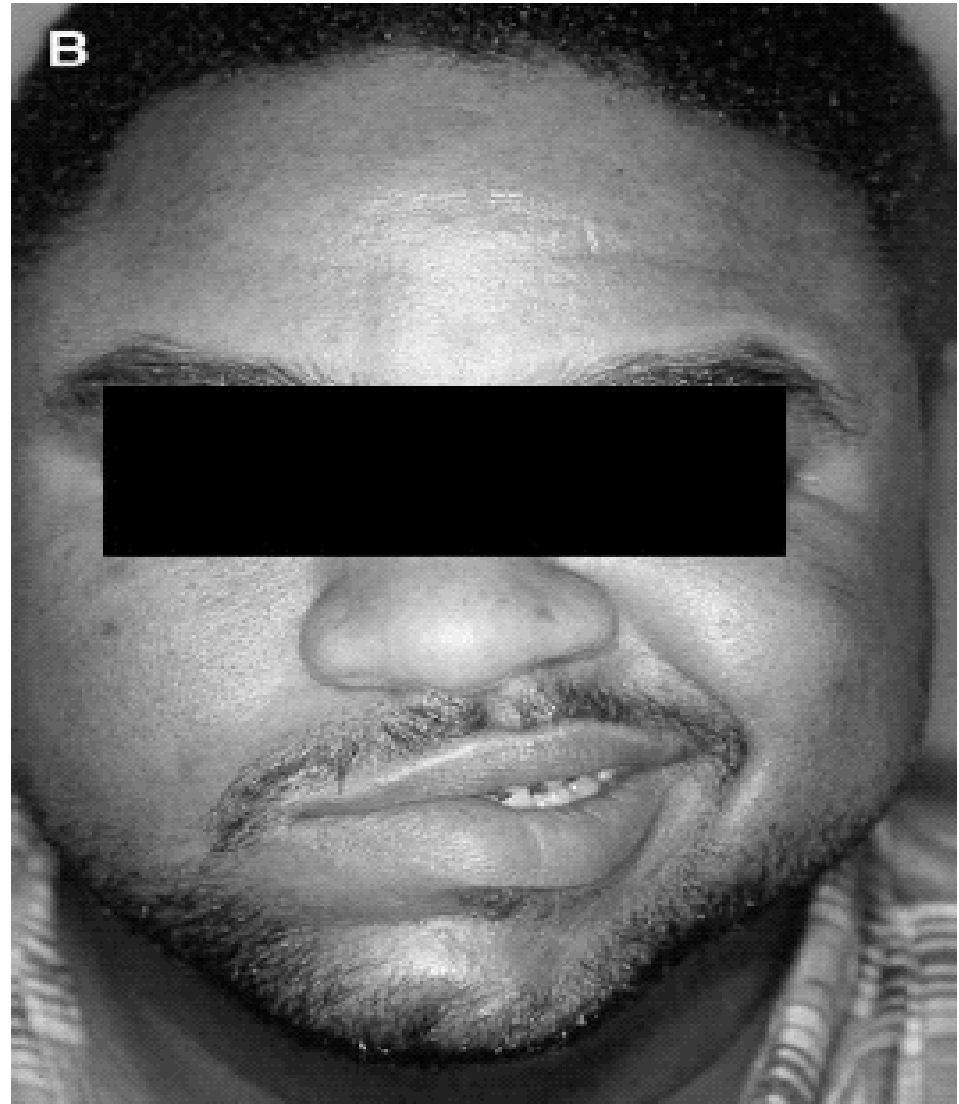
Examination shows:

Face at rest, smiling, raised eyebrows with deficit otherwise normal exam

Sensation is mildly increased

The examination of the ear is normal.

- What is the diagnosis?
- How much work-up is appropriate?



Acute and Chronic Neuropathies

- Answer:
- Bell's Palsy
- Physical exam only
- What if a vesicular lesion was found on ear exam?
- What would the diagnosis be?

Acute and Chronic Neuropathies

Case 4

A 25-year-old man presents with 3 days of gradual progressive difficulty walking
He is having weakness of his arms
He has had subjective heaviness in the legs, and mild tingling in the feet

Examination shows:

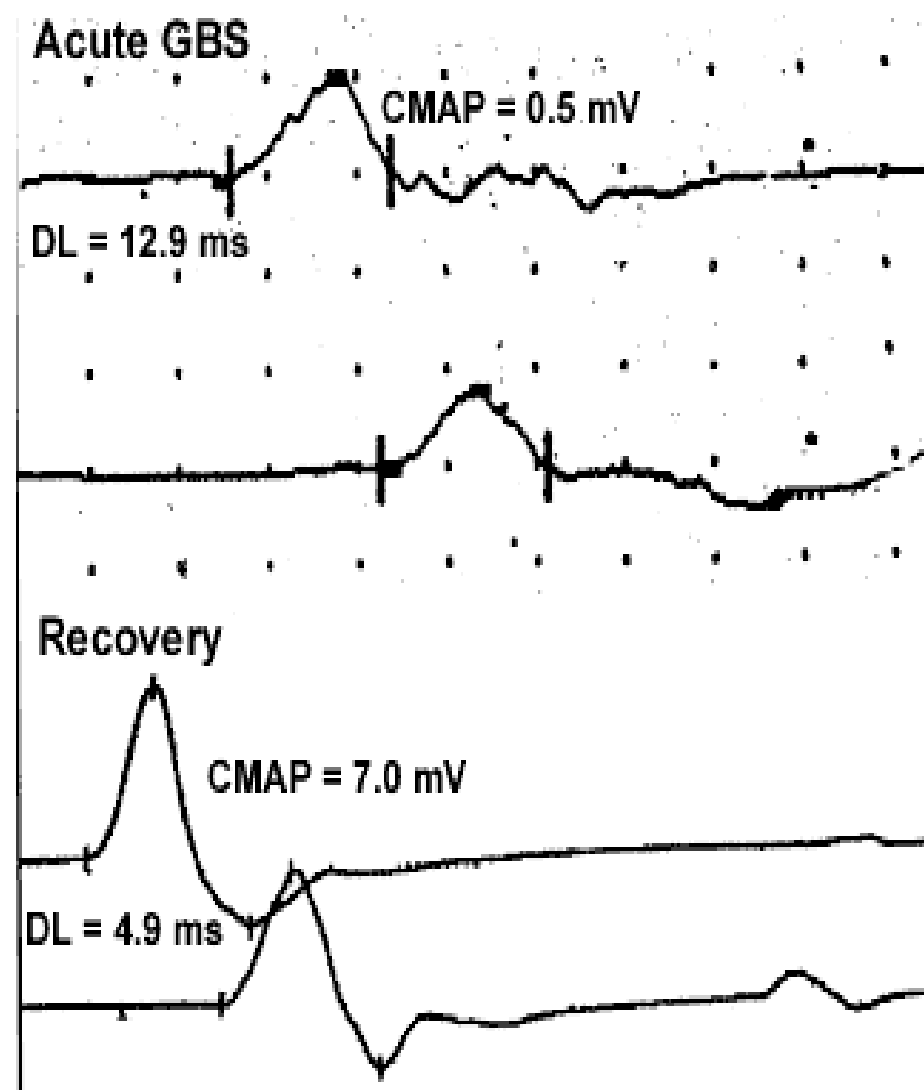
Moderate weakness of proximal and distal muscle groups (shoulders, arms, and legs in symmetric fashion).

There is mild decrease in position and vibration sense in the toes.

The muscle stretch reflexes are absent in the arms and legs.

He describes a mild respiratory illness 3 days before the onset of weakness.

- What is the diagnosis?



Acute and Chronic Neuropathy

- **Answer:**
- **Landry-Guillain-Barre**

Acute and Chronic Neuropathies

- **Case 6**

40-year-old woman presents with 15 years of gradual progressive difficulty with ambulation

Tendency to stumble easily;

Most recent difficulty with hand function including grip, strength, opening jars, and grasping fine objects.

The symptoms are symmetric.

There is minimal tingling in the toes but no sensory loss in the hands.

The examination shows the presence of atrophy in the foreleg muscles

Prominent tibial bones; atrophy of the intrinsic hand muscles and pes cavus.

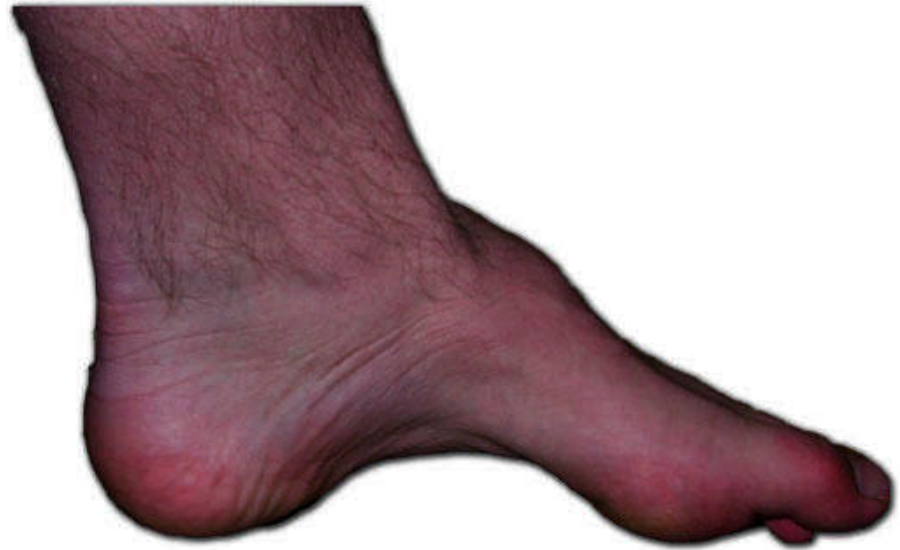The muscle stretch reflexes are absent

There is decreased vibration sense in the toes and fingertips, and slightly decreased pin prick in the toes.

There is associated foot drop bilaterally.

Proximal strength is normal.

Diagnosis?



Acute and Chronic Neuropathies

- Answer:
- Charcot-Marie-Tooth Disease

Acute and Chronic Neuropathies

• Case 7

A 51-year-old man presents with 3 weeks of continuous burning, stinging, and intense discomfort in the side of the leg as shown.

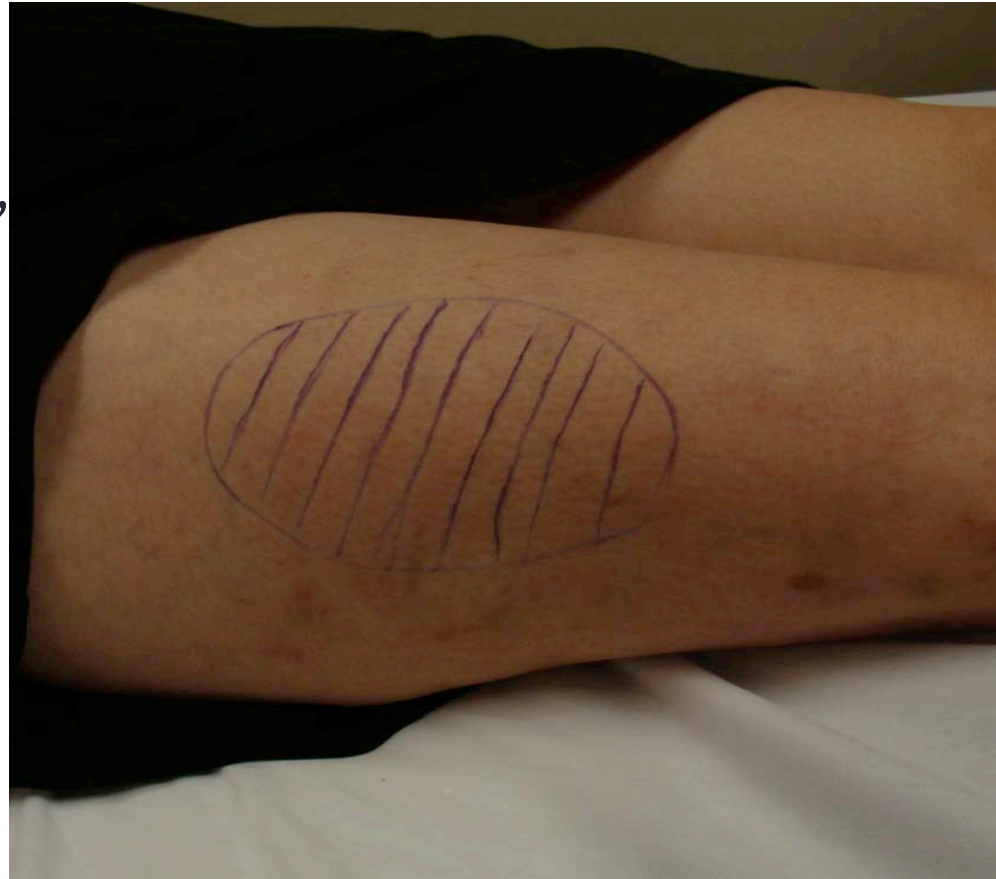He has no other past medical history, takes no medications, and has no back pain or leg weakness, and no recent viral symptoms.

Examination shows:

Super sensitivity in the circle area whether touched with a pin or with cotton, all stimuli are equally noxious.

Strength in the legs is normal as are the muscle stretch reflexes.

What is the diagnosis? Treatment?



Acute and Chronic Neuropathies

- **Answer:**
- Lateral femoral cutaneous neuropathy syndrome
 - *meralgia paresthetica*

Acute and Chronic Neuropathies

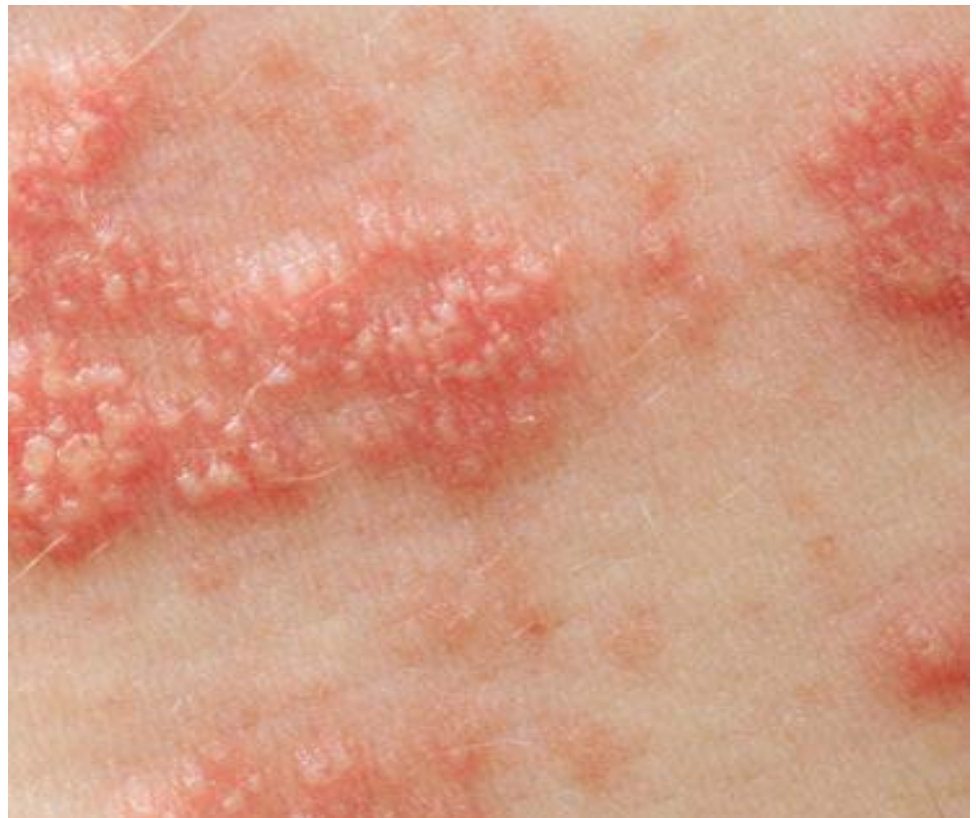• Case 8

53-year-old woman presents with 5 days of burning pain in the left posterior chest

It radiates around her side to the anterior chest in a band-like pattern.

She reports recent malaise, nausea, and vomiting.

In the last 24 hours she has developed clusters of vesicles on a red base in the area of burning pain.



What is the diagnosis?

Acute and Chronic Neuropathies

- **Answer:**

- Herpes Zoster

Acute and Chronic Neuropathies

Amyotrophic Lateral Sclerosis (ALS)

- Also known as “Lou Gehrigs Disease”
- Progressive Degenerative with muscle wasting
- Sensory and Cognitive changes
- Affects men more than women ages 40-60

Acute and Chronic Neuropathies

Clinical Manifestations:

Musculoskeletal

- Weakness/fasciculations/spasticity/paresis/hyperreflexia

Respiratory

- Dyspnea/Difficulty clearing airway

Nutrition

- Difficulty chewing/Dysphagia

Emotion

- Loss of control/ liability

Cognitive

Intellect intact

Acute and Chronic Neuropathies

Prognosis/Treatment:

Diagnosis is with EMG with objective and subjective findings

Death is usually resultant of pneumonia/respiratory failure

Treatment-

Riluzole (Rilutek) which extends life a few months

Edaravone(Radicava)- IV

Supportive nutrition/ventilation/communication/mobility

Respiratory compromise within 2-5 years of diagnosis

Acute and Chronic Neuropathies

MYOPATHIES

- Hereditary/Congenital

- Metabolic

- Inflammatory

- Toxic

Acute and Chronic Neuropathies

Work up for Myopathy

- CK with isoenzymes
- Electrolytes, calcium, magnesium
- Serum myoglobin
- Serum creatinine and BUN
- Urinalysis:
 - Myoglobinuria is indicated by positive urinalysis** with few RBCs on microscopic evaluation.
- Complete blood count
- Erythrocyte sedimentation rate
- Thyroid function tests
- Liver Functions
- EMG-NCV
- Age appropriate cancer screening
- Specific Genetic testing- Cadisil, MELAS, etc

Acute and Chronic Neuropathies

Duchenne Muscular Dystrophy

X linked

Progressive weakness

Begins at 6 months of life until young adult

Weakness: proximal > distal

Elevated CPK. Ultrasound muscles or EMG

Treatment-

-Exondys 51 –(eteplirsen)

-Spinraza-(nusinersen)-SMN 2

Acute and Chronic Neuropathies

Myotonic Dystrophy

Inherited neuromuscular disorder

Autosomal dominant

Symptoms-

- Weakness
- Sleep apnea
- Cardiac conduction defects
- Mitral valve prolapse
- Testicular atrophy

Acute and Chronic Neuropathies

Mitochondrial

- Mitochondrial myopathy (MELAS)
- Inherited maternal
- Defect of the mitochondria
- associated Lactic acidosis
- Muscle weakness/ptosis/neurological
- Cardiomyopathy - arrhythmias
- Liver/Kidney problems
- Stroke before 40
- Red ragged fibers on biopsy

Acute and Chronic Neuropathies

Metabolic

- Addison disease, particularly when fluid and electrolyte problems are present
- Cushing disease
- Hypothyroidism (CK may be mildly elevated)
- Hyperthyroidism (CK may be normal)
- Hyperparathyroidism
- Conn Syndrome

Acute and Chronic Neuropathies

Periodic Paralysis:

Normokalemic paralysis causes the **most severe and prolonged** attacks.

Patients usually feel well between attacks, but some have myotonia or residual weakness after repeated episodes.

Acute hypokalemic periodic paralysis may be primary (ie, familial) or secondary to excessive renal or GI losses or endocrinopathy.

Intracellular shift of potassium depolarizes the cell membrane rendering it inexcitable and no muscle contraction can occur.

Familial periodic paralysis usually occurs in Caucasian males, is autosomal dominant, and may last as long as 36 hours.

Attacks usually **occur at night or in early morning** upon awakening and can be precipitated by a diet high in carbohydrates, rest following exercise, or glucose and insulin given intravenously.

Acute and Chronic Neuropathies

• Inflammatory

- Dermatomyositis / Polymyositis
 - Proximal muscle weakness
 - EMG- myopathic changes consistent with inflammation
 - MRI- shows inflammatory component
 - **Responds to glucocorticoids**
- Inclusion Body Myositis
 - Does NOT respond to steroids
 - BX shows vacuolar inclusions with eosinophils

Acute and Chronic Neuropathies

Infections

Spirocete

Lyme

Bacterial

Staphylococcal ,Tuberculosis, Clostridium

Viral

HIV, Influenza, EBV, CMV, Coxsackie, Adenovirus

Acute and Chronic Neuropathies

Toxic

Ingestion of chemicals or pharmaceuticals:

ETOH-vitamin deficiencies

Statins/Fenofibrates- simvastatin

Steroids-iatrogenic myopathy

Interferon alpha-

Antibiotics-metronidazole, nitrofurantoin

Hydralazine-

Cardiovascular- Amiodarone, Captopril, Enalapril, Flecainide

Gout-colchicine, allopurinol

Acute and Chronic Neuropathies

Myasthenia Gravis

Autoimmune- motor end plate disorder

Associated with thymomas

Diplopia and ptosis is common

Symptoms worsen as day progresses

Diagnosis:

Anti-Acetylcholine receptor antibodies

Tensilon test (while ptosis present)

Treatment:

Anti-cholinesterase agents (mestinon)/
thymectomy

In crisis- Plasma exchange/IVIg

Acute and Chronic Neuropathies

Lambert-Eaton

- Associated with Oat cell carcinoma
- Autoimmune
- Presynaptic peripheral nerves antibodies that causes acetylcholine release to decrease
- Also known as LEMS myasthenic syndrome
- Proximal muscle weakness
- Dry mouth
- Hypo-reflexia- esp lower extremities

Treatment: Anti-cholinesterase agents